



Contents lists available at ScienceDirect

International Journal of Surgery Case Reports

journal homepage: www.casereports.com

Repair of a coccygeal hernia with a biological mesh



F. Hoexum*, R.J.C.L.M Vuylsteke

Kennemer Gasthuis, Haarlem, The Netherlands

ARTICLE INFO

Article history:

Received 10 October 2014

Received in revised form

27 November 2014

Accepted 8 December 2014

Available online 12 December 2014

Keywords:

Coccygeal

Hernia

Biologic mesh

Repair

ABSTRACT

Coccygeal herniation after coccygectomy is rare. Little is known about the management of this complication. We present a case of a 44 year old women with a coccygeal herniation 7 years after coccygectomy. She was treated two times for an infected pilonidal sinus with incision and drainage. After the last incision and drainage she had complaints of a painful swelling in the sacral area and difficulty with evacuation of her stools. A defaecography showed a coccygeal herniation. An additional MRI of the pelvic region showed a defect with a diameter of approximately 38 mm. We performed a hernia repair with a biological mesh (Strattice™ surgical mesh, LifeCell Corporation USA) via a sacral approach. Her recovery was complicated by a small wound dehiscence without clinical signs of infection. The sacral wound healed per secundam. Her complaints had completely disappeared. A defaecography 2 months after surgery showed no residual herniation. To our knowledge, it is the first reported case of a coccygeal hernia repair with a biological Strattice™ surgical mesh.

© 2014 The Authors. Published by Elsevier Ltd. on behalf of Surgical Associates Ltd. This is an open access article under the CC BY-NC-ND license (<http://creativecommons.org/licenses/by-nc-nd/3.0/>).

1. Introduction

Coccygectomy is performed in the surgical treatment of both malignant and benign tumours arising from the coccyx, such as sacrococcygeal teratoma or sacrococcygeal extraspinal ependymomas. Another less common indication for coccygectomy is coccygodynia, a condition characterised by pain or tenderness in the coccygeal region. A rare complication after coccygectomy is a coccygeal hernia. We present a case of a 44 year old women with a coccygeal herniation 7 years after coccygectomy.

2. Case report

A 34 year old woman was referred in August 2003 to our department with complaints of coccygodynia. She had experienced pain over the last 7 years in her coccygeal region during sitting or laying on her back. Conservative treatment with injections in the coccygeal region (presumably cortisone) in a hospital on Saint Martin did not provide a definite resolution of her complaints. Besides degenerative alterations at level L5-S1 no other abnormalities could be identified on plain X-rays. Our initial conservative treatment (kenacort injections) resulted in temporary relief of her complaints. In January 2005 a coccygectomy was performed via a transverse incision because of recurrent and refractory coccygodynia. Wound healing was initially complicated by a wounddehiscence without

clinical signs of infection after which the wound healed per secundam. Six months after the coccygectomy she visited the outpatients clinic with complaints of a small lump underneath her scar. An ultrasound showed partial bulging of her pelvic organs during a Valsalva manoeuvre. At that time no surgical intervention was deemed necessary and she was discharged from further follow up. In July 2006 and March 2013 an incision and drainage of an infected pilonidal sinus was performed. No abnormal findings were reported during each procedure. Three months after her last incision and drainage, she reported a painful swelling at the site of the last incision and drainage. The complaints worsened with increased intra-abdominal pressure during squeezing or coughing. Furthermore the process of evacuating stools was problematic, she had to apply manual pressure from the outside on the sacral swelling to be able to perform defecation. Physical examination showed a tender swelling at the site of her most recent incision and drainage of the pilonidal sinus with the clinical suspicion on a herniation of her bowel (Fig. 1a). A defaecography showed a coccygeal herniation (Fig. 1b). Defecation was only possible with manual pressure from the outside on the swelling whereby the herniation dissolved (Fig. 1c). An additional MRI showed a defect with a diameter of approximately 3,8 cm. Because of the risks of infection we elected a hernia repair with a biological (porcine) mesh (Strattice™ surgical mesh, LifeCell Corporation USA). Due to a possible hypersensitivity of the patient to pork, a cutaneous allergy-test was performed. No adverse reactions to the used material were seen. We performed a hernia repair via a Kraske approach with the patient in a jack knife position. The biological mesh was placed with a sub lay technique and secured with prolene (Johnson & Johnson Inc. USA) sutures. The fascia, sub cutis and skin were closes separately after placing a

* Corresponding author at: Kennemer Gasthuis Haarlem, Boerhaavelaan 22, 2035 RC Haarlem, The Netherlands. Tel. :+31 23 545354; fax: +31 23 5453649.

E-mail address: frankhoexum@hotmail.com (F. Hoexum).

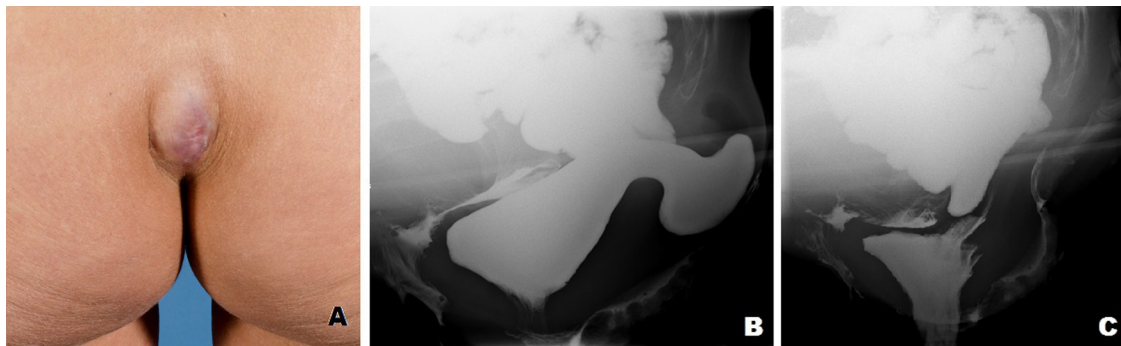


Fig. 1. Pre-operative photograph of the sacral region and defaecography.
 A = Tender swelling at the site of the last incision and drainage of an infected pilonidal sinus.
 B = Defaecography with the apparent coccygeal herniation.
 C = The osseous structures of the hand are seen on the right, the herniation resolves and defecation is possible.

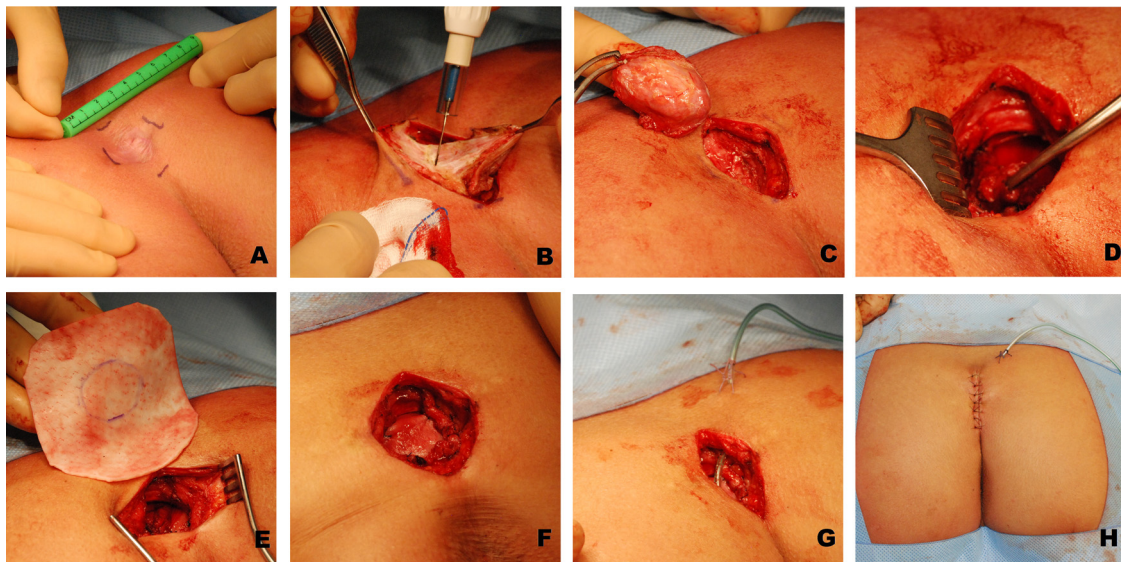


Fig. 2. Photo compilation of the hernia repair.
 The hernial sac is removed (A–C). The hernia site is clearly visible on image (D). The biological mesh is cut to size and positioned with a sublay technique and secured with prolene sutures (E and F). After a wound drain is placed, the wound is closed in layers (G and H).

wound drain (Fig. 2a–h). Her post-operative recovery was uncomplicated. The wound drain could be removed the 4th postoperative day and she was discharged the following day. On the 14th postoperative day the skin sutures were removed. Unfortunately the next day she was diagnosed with a wound dehiscence without any clin-

ical signs of infection. Her sacral wound healed per secundam over a period of two weeks (Fig. 3a). Her mechanical complaints were completely resolved by the operation. A defaecography 2 months after surgery showed no residual hernia in the coccygeal region (Fig. 3b). She was discharged from further follow up.

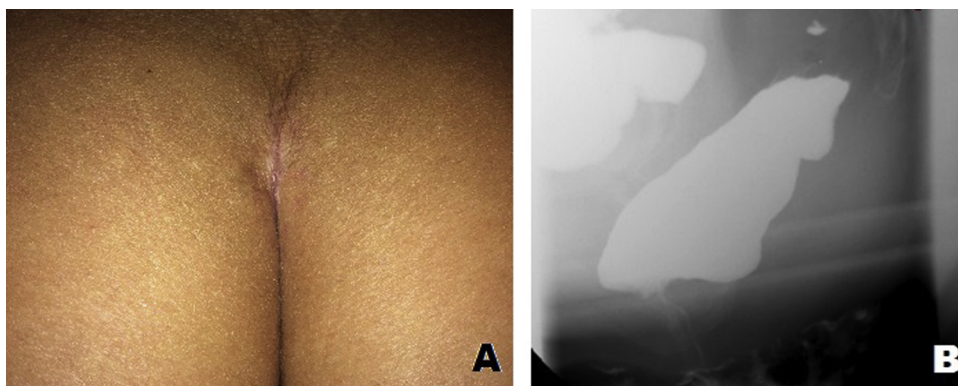


Fig. 3. Postoperative photograph and defaecography 2 months after surgery.

Table 1
Literature review.

Author (Year)	M/F	Age	Indication coccygectomy	Treatment	Success	Approach
Pagenstecher [6]	F	50	Coccygodynia	Herniorrhaphy	Yes	Sacral
Nichols [7]	M	38	Pain after trauma	Herniorrhaphy	Yes	sacral
Balkenende [8]	F	43	Block excision pilonidal sinus and coccyx	Herniorrhaphy	Yes	Sacral
Zook [9]	F	42	Chronic tailbone pain after trauma	1st mesh 2nd mesh 3rd gluteus maximus transposition	1st No; chronic wound, mesh dehiscence 2nd No; Infection 3rd Yes	Sacral Sacral Sacral
Garcia [10]	F	43	Posttraumatic coccygodynia	Mesh repair	Yes	Sacral
Kumar [11]	F	70	Sacro-coccygeal arthritis	Mesh repair	Yes	Abdominal
Miranda [12]	F	46	Coccygeal tumor	1st mesh (prevention) 2nd mesh 3rd VRAM flap	1st No; herniation 2nd No; recurrence hernia 3rd Yes	1st sacral 2nd sacral 3rd abdominal and sacral
Dugani [13]	F	71	coccygodynia	Mesh repair	Yes	Laparoscopic

F = female, M = male, VRAM = Vertical rectus abdominis myocutaneous.

3. Discussion

Coccygectomy is performed in the surgical treatment of both malignant and benign tumours arising from the coccyx, such as sacrococcygeal teratoma or sacrococcygeal extraspinal ependymomas [1,2]. Another less common indication for coccygectomy is coccygodynia, a condition characterised by pain or tenderness in the coccygeal region [3–5]. It could be the result of severe trauma, repetitive injury, post childbirth, local tumors, disk degeneration and of idiopathic nature. The exact pathophysiologic mechanisms associated with coccygodynia are still obscure, while obesity is considered as a predisposing factor due to the resulting pelvic rotation [3]. A rare complication after coccygectomy is a coccygeal hernia. Pagenstecher is believed to be the first to report a coccygeal herniation in a 50-year-old woman who had undergone a coccygectomy for coccygodynia [6]. To our knowledge, only 8 cases have been reported with a true coccygeal herniation [6–13]. Because of the small number of reported cases, little is known about the best treatment of this complication. Primary herniorrhaphy, mesh repair, muscle transposition and hernia repair with de-epithelialised musculocutaneous flaps have been described (Table 1,). Besides a direct sacral approach also anterior abdominal and laparoscopic procedures are mentioned. We chose a sacral approach because of the relatively mild invasiveness of this procedure compared with laparoscopic transabdominal approach. This approach is similar to the approach Paul Kraske presented in 1885 in a lecture at the Fourteenth Congress of the German Society of Surgery on the subject of the transsacral approach to the removal of rectal cancer [14]. Most evidence in the prevention or treatment of herniation in the pelvic region is related to perineal herniations after proctectomy or abdominal-perineal excision in the management of rectal malignancies. Mesh repair, musculocutaneous flaps and more recent biologic tissue matrix have been used in the prevention and treatment of pelvic herniations [15–18]. We performed a mesh repair with a biological tissue matrix derived from porcine skin because of the possible advantages in biocompatibility and suitability in infected wounds or those that are at high risk to develop infectious wound complications [17]. The use of this costly matrix was justified by analyzing the available literature. Of the seven non biological mesh repairs described in the literature, 4 were unsuccessful or complicated by infection (Table 1). Definite hernia repair had to be performed using major surgical procedures; e.g. gluteus maximus transposition or vertical rectus abdominis musculocutaneous (VRAM) flap reconstruction. Although based on small

numbers, we concluded that a 57% risk on failure and consequent re-hospitalization and re-intervention wasn't cost-effective.

4. Conclusion

The use of a biological mesh is feasible and effective in the surgical management of a coccygeal hernia. To our knowledge it's the first reported case of a coccygeal hernia repair with a biological mesh.

Conflicts of interest

Nothing to declare.

Sources for funding

Nothing to declare.

Consent

Written informed consent was obtained from the patient for publication of this case report and accompanying images.

Author contribution

Study design: FH, RV.
Data collections: FH, RV.
Data analysis : FH.
Writing: FH, RV.

References

- [1] H.O. Gabra, E.C. Jesudason, H.P. McDowell, B.L. Pizer, P.D. Losty, Sacrococcygeal teratoma—a 25-year experience in a UK regional center, *J. Pediatr. Surg.* 41 (September (9)) (2006) 1513–1516.
- [2] T. Aktuğ, G. Hakgüder, S. Sarioğlu, F.M. Akgür, M. Olguner, U. Pabuçcuoğlu, Sacrococcygeal extraspinal ependymomas: the role of coccygectomy, *J. Pediatr. Surg.* 35 (March (3)) (2000) 515–518.
- [3] E.J. Karadimas, G. Trypsiannis, P.V. Giannoudis, Surgical treatment of coccygodynia: an analytic review of the literature, *Eur. Spine J.* 20 (May (5)) (2011) 698–705.
- [4] E.E. Kerr, D. Benson, R.J. Schrot, Coccygectomy for chronic refractory coccygodynia: clinical case series and literature review, *J. Neurosurg. Spine* 14 (May (5)) (2011) 654–663.
- [5] A. Ramieri, M. Domenicucci, P. Cellocchio, M. Miscusi, G. Costanzo, Acute traumatic instability of the coccyx: results in 28 consecutive coccygectomies, *Eur. Spine J.* 22 (November (Suppl. 6)) (2013) 939–944.

- [6] G.A. Pagenstecher, Coccygeal hernia, *JAMA* 95 (November (21)) (1930) 1588.
- [7] R.A. Nichols, A.L. Herring, Coccygeal hernia, *JAMA* 101 (August (9)) (1933) 674.
- [8] U. Balkenende, B.P. Van Leeuwen, A.X. Ginai, Hernia through a scar on the posterior rectal wall, *Eur. J. Surg.* 162 (1996) 347–348.
- [9] N.L. Zook, E.G. Zook, Repair of a long-standing coccygeal hernia and open wound, *Plast. Reconstr. Surg.* 100 (July (1)) (1997) 96–99.
- [10] F.J. García, J.D. Franco, R. Márquez, J.A. Martínez, J. Medina, Posterior hernia of the rectum after coccygectomy, *Eur. J. Surg.* 164 (October (10)) (1998) 793–794.
- [11] A. Kumar, J.R. Reynolds, Mesh repair of a coccygeal hernia via an abdominal approach, *Ann. R. Coll. Surg. Engl.* 82 (March (2)) (2000) 113–115.
- [12] E.P. Miranda, A.L. Anderson, A.S. Dosanjh, C.K. Lee, Successful management of recurrent coccygeal hernia with the de-epithelialised rectus abdominis musculocutaneous flap, *J. Plast. Reconstr. Aesthet. Surg.* 62 (January (1)) (2009) 98–101.
- [13] S. Dugani, Q.H. Tran de, R.J. Finlayson, Incidental detection of bowel herniation with ultrasonography and fluoroscopy during a caudal block, *Can. J. Anaesth.* 58 (June (6)) (2011) 551–554.
- [14] L.M. Corman, Classic articles in colonic and rectal surgery, *Dis. Col. Rect.* 27 (1984) 499–503.
- [15] H.Z. Butt, M.K. Salem, B. Vijaynagar, S. Chaudhri, B. Singh, Perineal reconstruction after extra-levator abdominoperineal excision (eLAPE): a systematic review, *Int. J. Colorectal Dis.* 11 (November (28)) (2013) 1459–1468.
- [16] J.D. Foster, S. Pathak, N.J. Smart, G. Branagan, R.J. Longman, M.G. Thomas, N. Francis, Reconstruction of the perineum following extralevator abdominoperineal excision for carcinoma of the lower rectum: a systematic review, *Colorectal Dis.* 14 (September 9) (2012) 1052–1059, <http://dx.doi.org/10.1111/j.1463-1318.2012.03169.x>.
- [17] D. Stamatou, J.E. Skandalakis, L.J. Skandalakis, P. Mirilas, Perineal hernia: surgical anatomy, embryology, and technique of repair, *Am. Surg.* 76 (May (5)) (2010) 474–479.
- [18] M. Hübner, D. Streit, D. Hahnloser, Biological materials in colorectal surgery: current applications and potential for the future, *Colorectal Dis.* 14 (December (Suppl. 3)) (2012) 34–39, <http://dx.doi.org/10.1111/codi.12048>, Review.

Open Access

This article is published Open Access at sciendo.com. It is distributed under the [IJSCR Supplemental terms and conditions](#), which permits unrestricted non commercial use, distribution, and reproduction in any medium, provided the original authors and source are credited.