

# Treatment of Intractable Coccygodynia by Transsacral Ammonium Chloride Injection

BALLARD D. WRIGHT, M.D.

Uppsala, Sweden\*

**T**HE PATIENT with coccygodynia is often abandoned because of the failure of recommended conservative treatment and the physician's hesitancy to recommend more radical forms of therapy. Furthermore, mutual dissatisfaction often leaves the patient labeled as neurotic and the physician as inadequate. Both perceptions result from frustration with current therapeutic vogues and handicap continued therapeutic efforts.

Fortunately, most cases of a painful coccyx abate within a few months unless an exacerbation is precipitated by recurrent trauma. This report describes the successful treatment of 10 out of 12 patients with coccygodynia of from 6 months to 15 years duration.

## ANATOMY AND PHYSIOLOGY

The coccyx is attached to the sacrum at the sacrococcygeal joint, where both afford

origin to numerous ligamentous and muscular structures that make up the pelvic floor. This accounts for the high incidence of injuries that arise during pregnancy and childbirth. These structures are innervated by nerves derived from the sacral and coccygeal plexuses. The coccyx itself probably derives its sensory distribution from the dorsal divisions of the last two sacral and coccygeal nerves, which unite on the back of the sacrum to supply sensory endings to the coccyx<sup>1</sup> (fig. 1). The ventral ramus of the fourth sacral nerve may be important through its contribution to the anococcygeal plexus; its primary role, however, appears to be through its contributions to the pudendal, inferior rectal, and perineal nerves, which are mixed motor and sensory nerves, to pelvic and perineal structures.<sup>2</sup>

Coccygodynia shows many similarities to neuralgic states and probably should be so

\*Department of Anaesthesia, Akademiska Sjukhuset, Uppsala, Sweden.

Address reprint requests to: Department of Anesthesiology, University of Kentucky, College of Medicine, Lexington, Kentucky 40506.

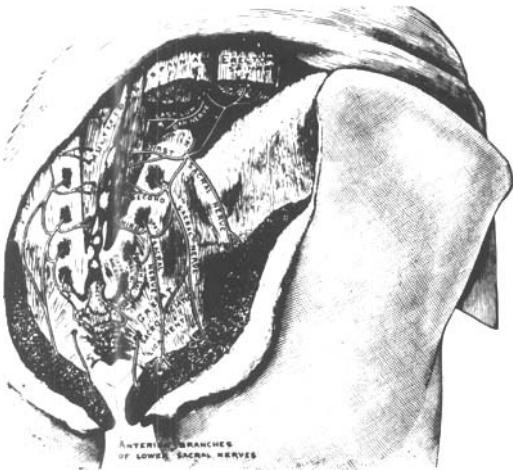


FIG. 1. Dorsal divisions of the sacral nerves. (From Gray H: *Anatomy of the Human Body*, 28th Edition. Philadelphia, Lea & Febiger, 1968. Page 958. By permission.)

classified. The pain has a restricted anatomic distribution and, although usually involving the whole coccygeal area, may be unilateral. It generally follows a recognized event of physical trauma; in all our cases there was severe anterior angulation of the coccyx.

It is interesting that 11 of the 12 of our patients were female. Pregnancy either precipitated or aggravated the disease in 4 of these patients and a fall was incriminated in 7 (table 1). However, neoplastic, toxic, and inflammatory causes should be searched for. Bohm<sup>3</sup> found macroscopic and microscopic evidence of neural degeneration of nerve roots in 1 patient, presumably due to compression from a swollen filum terminale. The resemblance of coccydynia to posterior occipital neuralgia is striking, both involving posterior rami of spinal nerves but at opposite ends of the cord. Dorsal rhizoto-

mies abolish pain in both entities but the sensory loss at the rostral end of the cord is more disabling. A peculiar similarity is that both the first (C<sub>1</sub>) and the last (coccygeal) nerves apparently are not involved in either entity.

The use of ammonium salts for relief of pain in neuralgic states originated in 1931 with Judovich and Bates,<sup>4</sup> who reported on the successful use of a 0.75 percent solution of ammonium sulfate in 5000 cases. Confirmatory studies by other investigators were unrewarding until a stronger concentration was tried. Work by Dam<sup>5,6</sup> in Denmark, with a solution of 5 to 15 percent ammonium salts, has produced favorable results in several thousand patients, with no serious sequelae. A report on a small series of patients in this country gave favorable but tenuous conclusions.<sup>7</sup> Our experience in a wide variety of pain states has demonstrated the usefulness of 7 to 15 percent ammonium chloride (NH<sub>4</sub>Cl) in producing protracted pain relief.<sup>8</sup>

The exact mechanism by which ammonium salts produce pain relief is unknown. Original work by Judovich attributed it to the selective destruction of the unmyelinated C fibers. This is in agreement with the gate-control theory of pain, which suggests that neuralgic pain occurs because of an increased firing at the gate (substantia gelatinosa) by the small unmyelinated fibers. Ammonium chloride may reduce the number and frequency of impulses arriving at the cord.<sup>9</sup>

#### MATERIALS AND METHODS

All patients referred to the Anesthesia Service had received prior evaluation and treatment by the Orthopedic Service. Therapy had consisted of multiple local injections of the sacrococcygeal joint with a

★ BALLARD D. WRIGHT, M.D. is a Research Fellow in the Department of Anesthesiology of the University of Kentucky who is currently working in the Departments of Anesthesiology and Clinical Physiology at Uppsala University, Uppsala, Sweden. A graduate of the University of Kentucky College of Medicine, Dr. Wright served his Internship and Residency in Anesthesiology at Wilford Hall USAF Hospital, San Antonio, Texas.



TABLE 1  
Patient Data, Ammonium Chloride Injections for Coccygodynia

Case	Age	Duration of pain	Precipitating cause	Nerve block (s)	Time of repeat block	Time patient pain free	Comments
1	39	15 years	Childbirth	Bilateral S <sub>4</sub>	None	1½ years	None
2	36	6 months	Unknown	Bilateral S <sub>4</sub> Bilateral S <sub>5</sub>	6 weeks	2 years	After S <sub>4</sub> block, patient still experienced pain localized at tip of coccyx. Bilateral S <sub>5</sub> block done at 6 weeks along with repeat S <sub>4</sub> block. Patient experienced deep pain (not severe) radiating into right buttock for 1 week following blocks
3	21	9 years	Fall, aggravated by pregnancy	Bilateral S <sub>4</sub>	1 week	15 months	Patient experienced unpleasant sensation, "a puffed up balloon," in coccyx for several days following injection
4	32	10 years	Fall, aggravated by pregnancy	Bilateral S <sub>4</sub>	1 week	15 months	Initial block failed to completely eradicate pain. Repeat S <sub>4</sub> block totally successful
5	21	2 years	Fall	Bilateral S <sub>4</sub> Repeat S <sub>4</sub> on left	10 days	9 months	Following initial S <sub>4</sub> block, pain persisted at left side of coccyx. Repeat S <sub>4</sub> injection eradicated pain
6	26	9 years	Fall, aggravated by pregnancy	Bilateral S <sub>4</sub> and caudal; unsuccessful S <sub>5</sub>	1 week	Partially 6 months	Pain remained at tip of coccyx following S <sub>4</sub> block (repeated at 1 week). Eradicated by caudal but unable to perform S <sub>5</sub>
7	30	2 years	Unknown	Bilateral S <sub>4</sub> Bilateral S <sub>5</sub>	20 weeks	3 months	Pain relief for 5 months, then required 2 blocks to eradicate pain
8	28	1 year	Unknown	Bilateral S <sub>5</sub>	12 weeks	Partial	Relief for 3 months. Reblocked S <sub>5</sub> . Has received only fair relief
9	48	1 year	Fall	Bilateral S <sub>4</sub> Bilateral S <sub>5</sub>	12 weeks	1 month	Relief for 3 weeks, then required 2 repeat blocks
10	50	1 year	Fall	Bilateral S <sub>4</sub> Bilateral S <sub>5</sub> Repeat S <sub>4</sub> on left	8 weeks	2 months	Relief for 2 months, then recurrence unilaterally on left
11	39	1½ years	Unknown	Bilateral S <sub>4</sub>	8 weeks	2½ months	Relief 2 months, then required 1 repeat S <sub>4</sub> block
12	28	1 year	Fall	Bilateral S <sub>4</sub> Bilateral S <sub>5</sub>	None	6 months	None

steroid-local-anesthetic combination. Without exception this treatment had failed in these patients, some having had intermittent trials over many years. The workup included radiographic films of the lumbosacral spine and coccyx.

Before these patients were accepted as candidates for ammonium chloride block these criteria were met:

1. Pain present longer than 6 months and unrelieved by previous conservative measures.

2. Pain reproduced and aggravated by firm palpation of the coccyx but relieved by block of S<sub>4</sub> and/or S<sub>5</sub> nerves with local anesthetic agents.

3. No evidence of lumbosacral disc extrusion or chronic low back syndrome; presence of these entities would contraindicate nerve block therapy.<sup>10</sup>

Nerve blocks of the first 6 patients were begun according to the following protocol:

First visit: Injection of 2 ml. of 1 percent lidocaine in each foramina.

Second visit: Injection of foramina with 2 ml. of 1.5 percent lidocaine with epinephrine.

Third visit: Injection of foramina with 2 ml. of 0.2 percent tetracaine with epinephrine.

Fourth visit: Injection of foramina with 2 ml. of 7 percent NH<sub>4</sub>Cl.

Blocks were given to the fourth or fifth sacral nerves according to the pain distribution noted during palpation of the coccyx. This was done with the index finger feeling the anterior coccygeal surface rectally and the thumb externally palpating the posterior surface. If block of one set failed to relieve pain, the other was blocked as well.

The following method was used on the second group of 6 patients in the last half of this study:

First visit: Examination and injection of sacral nerves with 2 percent lidocaine.

Second visit: Placebo injection of saline solution.

Third visit: Injection of unknown solution of 2 percent lidocaine or 10 percent NH<sub>4</sub>Cl, using a double-blind approach.

Subsequent visits: If the patient received no pain relief, injections with an unknown

agent were continued until pain was relieved. If the patient received relief for longer than 2 weeks the key was broken. Subsequent blocks, if any, for these patients were always with 15 percent NH<sub>4</sub>Cl.

## RESULTS

Excellent results have been achieved in 10 of the 12 patients (83 percent) treated with transsacral NH<sub>4</sub>Cl injection. Five of these 10 have been pain free for over a year. These all belong to the first group of 6 patients. In the second group of 6 patients, one has been pain free for 6 months. Four have had variable periods of relief ranging from 2 to 4 months initially.

Fifty percent of the patients required blocking of only one set of segmental nerves, the majority requiring S<sub>4</sub> blockade. Furthermore, on two repeat blocks only a single nerve needed injection (tables 1 to 3).

A number of repeat blocks were performed in the first weeks, predominately in the first group of patients who had received initially only 2 ml. of 7 percent NH<sub>4</sub>Cl solution. The distribution of repeat blocks in the 8 to 16-week period is remarkable in that all patients belong to the second group, in whom the double-blind approach was used. Concentrations of drug in this group used initially were 5 ml. of 10 percent ammonium chloride.

TABLE 2  
Distribution of NH<sub>4</sub>Cl Nerve Blocks

Nerves blocked	Number of patients	Number of patients requiring repeat block	Total number of repeat blocks
S <sub>4</sub> blocks	5	4*	6
S <sub>5</sub> blocks	1	1	1
S <sub>4</sub> and S <sub>5</sub> blocks	6	5*	6
Totals	12	10	13

\*One patient required repeat block of single nerve unilaterally.

TABLE 3  
Results of NH<sub>4</sub>Cl Nerve Blocks in 12 Patients

	Excellent	Fair	Poor
S <sub>4</sub> blocks	5		
S <sub>5</sub> blocks		1	
S <sub>4</sub> and S <sub>5</sub> blocks	5		1
Totals	10 (83.3%)	1 (8.3%)	1 (8.3%)

The following case reports are illustrative of the 12 cases and the problems encountered.

Results were unsatisfactory in 1 patient, due to inability to locate and inject the S<sub>5</sub> nerves. She had an anatomic variant of the sacral hiatus, probably because of a bony overgrowth.<sup>11</sup>

### CASE REPORTS

*Case 1.*—The patient was a 39-year-old woman, with onset of coccygeal pain 15 years ago. The pain appeared following childbirth and continued to grow worse over the years, despite numerous therapeutic efforts. She could not sit for long periods and was unable to take car trips of longer than 1 hour. She had received numerous injections of steroids in the coccygeal region without benefit.

The patient's coccyx was antroverted. Pain was experienced on palpation over the main body of the coccyx but not at the tip. X-ray films of the lumbosacral spine were negative. Local anesthetic blocks, given according to the protocol, gave total relief of the pain and she could tolerate maximum pressure on the coccyx upon palpation. Each of the posterior rami of the S<sub>4</sub> sacral nerves was injected with 2 ml. of 7 percent NH<sub>4</sub>Cl solution with 1.66 percent lidocaine. The patient experienced intense but brief pain localized in the body of the coccyx, followed by anesthesia over the S<sub>4</sub> dermatomes. This lasted for the duration of the local-anesthetic effect. The coccyx remained free of tenderness on all followup examinations, without evidence of sensory loss, interference with sphincter function, or tissue reaction. The patient has remained pain free for 1½ years.

*Case 2.*—This patient was a 26-year-old woman with a 9-year history of coccygeal pain. She dated onset from a traumatic fall. The pain became worse following each of two pregnancies, especially over the previous year. She received no relief from multiple local-anesthetic-steroid injections into the coccyx.

Physical examination revealed an anteriorly angulated coccyx, painful to palpation, especially at the tip. X-rays were unremarkable. As initial attempts at caudal block were unsuccessful, the patient was given a local injection at the S<sub>4</sub> foramina. This did not result in complete relief, so a larger volume of local drug was injected. The pa-

tient obtained total relief, and sensory testing revealed anesthesia spread to the S<sub>3</sub> and S<sub>5</sub> nerves. Injection of 2 ml. of NH<sub>4</sub>Cl-lidocaine mixture at S<sub>4</sub> produced partial relief. Palpation of the body of the coccyx was well tolerated but tenderness remained at the tip.

After several attempts, a needle was introduced through the sacral hiatus, confirmed by successful caudal block and elimination of coccygeal pain. The needle was withdrawn to the approximate entry into the sacral canal; however, the S<sub>5</sub> nerves could not be located with the nerve stimulator. Despite this, 3 ml. of NH<sub>4</sub>Cl-lidocaine solution was injected. No paresthesias were experienced and the patient failed to obtain pain relief.

Followup confirmed the tip of the coccyx to be painful. Although the patient's original estimate of her lessening of pain was 50 to 60 percent, she has since decreased her estimate to about 30 to 35 percent.

### DISCUSSION

Our treatment places major emphasis upon transsacral block of the dorsal rami of the fourth and fifth sacral nerves. The sacral foramina are identified by methods described in standard texts of regional anesthesia.<sup>12,13</sup> Correct position is verified by unilateral stimulation of the ventral ramus of S<sub>4</sub>, with the needle electrode positioned deep into the foramina (fig. 2). At low voltage, motor fibers are stimulated, to give unilateral contraction of the external sphincter ani muscle.<sup>14</sup>

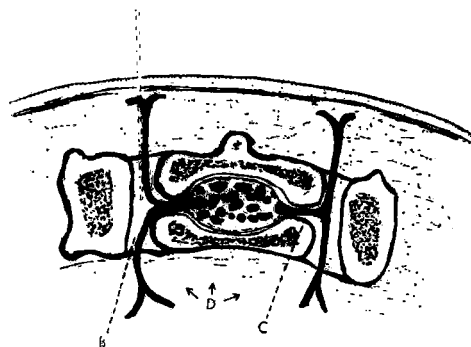


FIG. 2. Schematic representation of a cross-section through the sacrum at the level of S<sub>3</sub>. (A) needle in (B) sacral foramen. (C) division of sacral nerve into anterior and posterior primary divisions. If needle is advanced too far, it may easily be introduced into the pelvis (D). (From Adriani J: *Nerve Blocks: A Manual of Regional Anesthesia for Practitioners of Medicine*. Springfield, Illinois, Charles C Thomas, Publisher, 1954. Page 63. By permission.)

Stimulation at a higher voltage caused paresthesias along the pudendal and perineal nerves, which were felt in the labiae or scrotum and around the anus. If the patient complained of paresthesias predominantly in the lateral buttock down the posterior thigh and behind the knee, the ventral ramus of  $S_3$  was being stimulated. Upon identification of the ventral ramus of  $S_4$ , the needle was withdrawn about 0.5 to 1 cm. and the nerve was again stimulated at low voltage. Paresthesias into the main body of the coccyx and overlying skin was proof of the identity of the dorsal branch of  $S_4$ .

The fifth sacral nerve may be blocked as it emerges at the sacral hiatus; its exit is variable, being either medial or lateral to the cornua. Stimulation of this nerve will produce paresthesias into the tip of the coccyx and perianally; it apparently has no motor fibers.

Determination of the rami to be blocked was initially based upon the observation that pain localized at the sacrococcygeal joint was usually eliminated by  $S_4$  block; pain at the coccygeal tip was relieved by  $S_5$  block. If the pain was general or poorly localized at the coccyx, both the  $S_4$  and  $S_5$  rami were injected. Interestingly, 2 of the patients returned with pain on one side of the coccyx and a single unilateral nerve block was curative.

The 2 patients who had poor results both required  $S_5$  nerve block.  $S_4$  blocks failed to remove the pain but caudal block with a local anesthetic agent, which presumably blocked  $S_5$ , completely eradicated coccygeal pain. One of these was the patient who had the abnormal bony growth over the sacral hiatus which made it impossible to locate the  $S_5$  nerves. Location of the  $S_5$  nerve as it emerges from the sacral hiatus may be difficult and requires the use of a nerve stimulator.

The reblocks in the first group (table 4) occurred in patients who had initially received a weaker solution of  $NH_4Cl$  in a smaller volume. Any patient in this group who did not respond to the initial injection was subsequently injected with a larger volume (5 ml.) of a stronger solution (15 percent). This may account for the notable long-term success in this group (5 for longer than 1 year). A direct relationship between total mass of drug and nerve destruction is assumed, but this amount must be empirically found for each patient. By the same

TABLE 4  
Average Length of Time Between Initial and Repeat  $NH_4Cl$  Nerve Blocks

	Less than 2 weeks	2 to 8 weeks	8 to 16 weeks	More than 16 weeks
$S_4$ blocks	4*	2 (1)*		
$S_5$ blocks			1	
$S_4$ and $S_5$ blocks		1	2	3
Totals	4	3	3	3

\*First group of 6 patients.

reasoning, one may account for the distribution of blocks in the second group, where pain recurred at 8 to 16 weeks. Here the initial dose injected was 5 ml. of 10 percent  $NH_4Cl$ . Apparently enough fibers were destroyed to relieve the pain until regeneration of fibers to some critical number occurred.

### CONCLUSIONS

It is too early to say whether reblock in this group with 15 percent  $NH_4Cl$  will result in permanent pain relief. However, it can be categorically stated that all patients receiving  $NH_4Cl$  injections received some pain relief for variable periods of time. The optimum dosage of  $NH_4Cl$  appears to be in the neighborhood of 3 to 5 ml. of 10 to 15 percent. A critical variable is the distance that the drug can be placed from the nerve and remain effectively lytic.

Saline placebos were given to all in the last group of 6 patients and all had negative responses. However, a placebo situation was present in the first part of the study, as observed in the relief time responses from the various solutions of local anesthetic agents. Based upon these observations, all were ultimately judged negative responders. We recognize that as many as one third of patients receiving block therapy may show a placebo effect;<sup>15</sup> precisely because of this possibility, the second half of the study comprised a placebo injection, double-blind control, and use of a second observer.

None of the patients had distressing sequelae from their injections. There was no loss of sensory modalities but several had a zone of hypesthesia, not disturbing, which gradually disappeared. Despite the fact that the drug could, theoretically, spread to the ventral nerve roots no evidence of such was observed.

The procedure described is simple and can be performed by any physician experienced in regional anesthetic technics, in

contrast with anesthetic technics, and allows treatment of a greater number of patients.

### SUMMARY

Treatment of intractable coccygodynia by injection of ammonium chloride into dorsal rami of sacral nerves IV and V is described. Ten of 12 patients had complete pain relief following one or more injections of  $\text{NH}_4\text{Cl}$ . One failure was from inability to locate and block the  $\text{S}_5$  nerves because of an abnormality of the sacral hiatus. This patient and another received only partial relief of pain. Transsacral  $\text{NH}_4\text{Cl}$  block is recommended as a safe and effective alternative to coccygectomy and dorsal rhizotomy.

### ACKNOWLEDGMENT

I wish to express my thanks to Lea & Febiger for allowing me to use figure 1, and to Dr. John Adriani and Charles C Thomas, Publisher, for the use of figure 2.

### Generic and Trade Names of Drugs

Lidocaine—Xylocaine

Tetracaine—Pontocaine

### REFERENCES

- Goss CM: Gray's Anatomy. Philadelphia, Lea & Febiger, 1968, pp 958 and 1009
- Woodburne RT: Essentials of Anatomy. New York, Oxford University Press, 1961, pp 471-502
- Bohm E: Late results of sacral rhizotomy in coccygodynia. Acta Chir Scand 123:6-8, 1962
- Judovich B, Bates W: Segmental Neuralgias in Painful Syndromes. Philadelphia, FA Davis Company, 1944, pp 225-234
- Dam WH: Therapeutic blockades. Acta Chir Scand Suppl 343:89-101, 1964-65
- Dam WH: Personal correspondence to AJ DiGiovanni
- Davies JI, Steward PB, Fink P: Prolonged sensory block using ammonium salts. Anesthesiology 28:244-245, 1967
- Wright BD, DiGiovanni AJ: Unpublished data
- Melzack R, Wall PD: Pain mechanism: new theory. Science 150:971-979, 1965
- Crenshaw AH: Campbell's Operative Orthopedics. Fourth Edition. St. Louis, CV Mosby Company, 1963, pp 828-829
- Hingson RA, Hellman LM: Anesthesia for Obstetrics. Philadelphia, JB Lippincott Company, 1956, pp 85-86
- Adriani J: Nerve Blocks: A Manual of Regional Anesthesia for Practitioners of Medicine. Springfield, Illinois, Charles C Thomas, Publisher, 1954, pp 61-64
- Moore DM: Regional Block, A Handbook for Use in the Clinical Practice of Medicine and Surgery. Springfield, Illinois, Charles C Thomas, Publisher, 1965, pp 473-480
- Wright BD: A new use for the Block-Aid Monitor. Anesthesiology 30:237, 1969
- Papper EM: Regional anesthesia, a critical assessment of its place in therapeutics. Anesthesiology 28:1076-1077, 1967

Be not disturbed at being misunderstood; be disturbed rather at not being understood.

—Chinese Proverb